

OOGPROBLEMEN BINNEN DE GERIATRIE

Dr. Chantal Vulsteke



OOGPROBLEMEN BINNEN DE GERIATRIE

Normale evolutie

- ° Presbyopie
- ° Drogere ogen

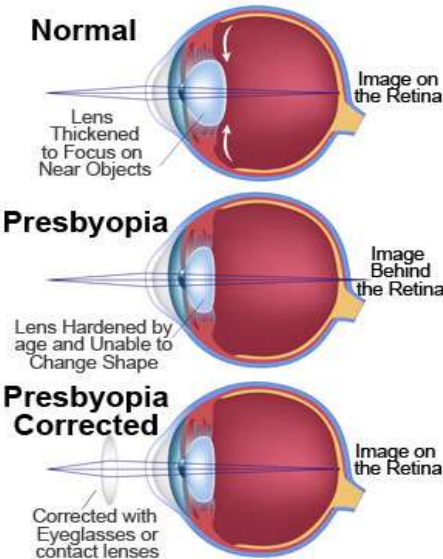
Pathologische evoluties

- ° glaucoom
- ° mediatroebelingen: cataract
- ° netvliesproblemen
 - ° leeftijdsgebonden maculopathie (LMD)
 - ° trombose (veneus, arterieel)
- ° neurologische problemen

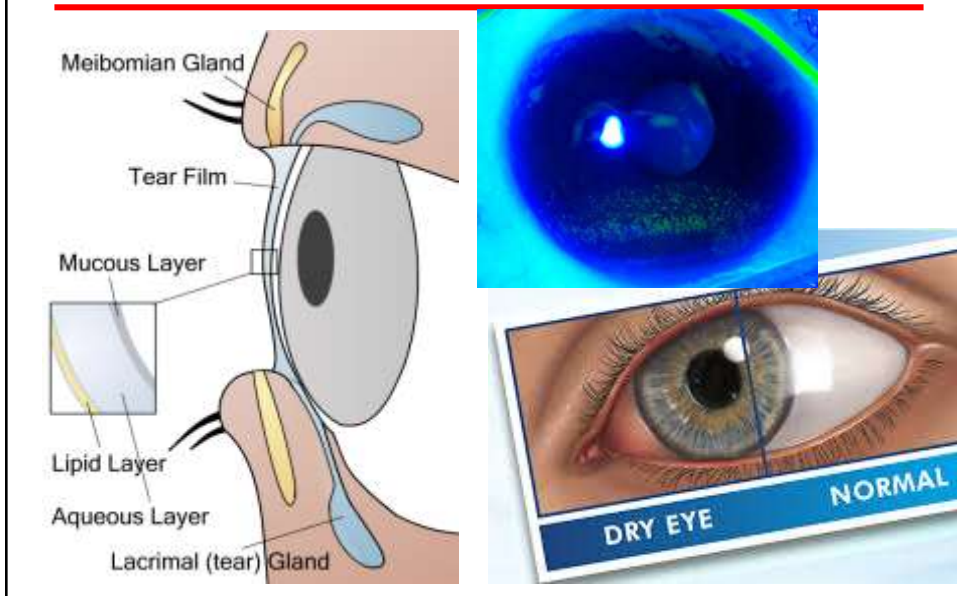
PRESBYOPIE



PRESBYOPIE



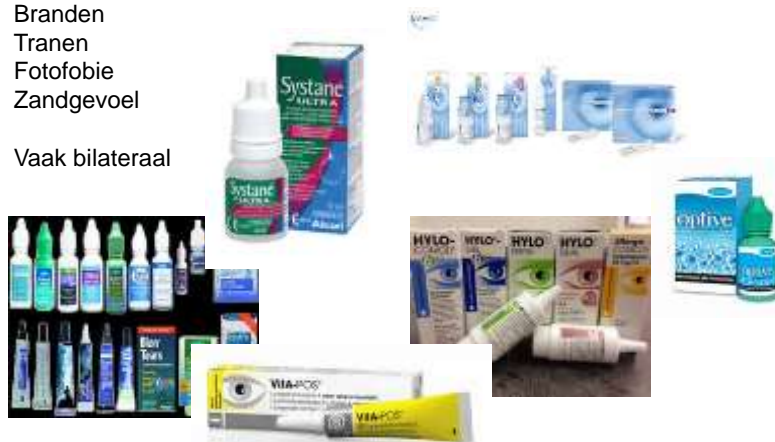DROGERE OGEN "Keratoconjunctivitis sicca"



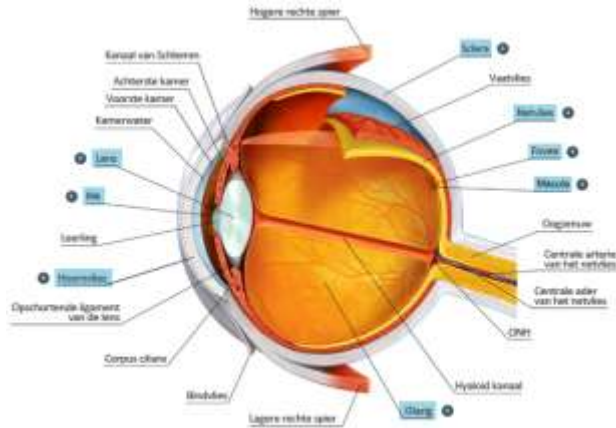
DROGERE OGEN

Pieken
Branden
Tranen
Fotofobie
Zandgevoel

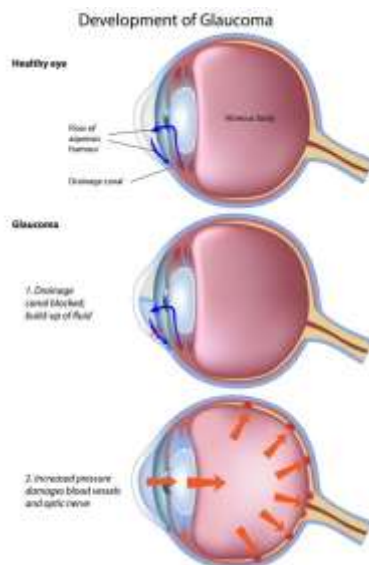
Vaak bilateraal



ANATOMIE



GLAUCOOM

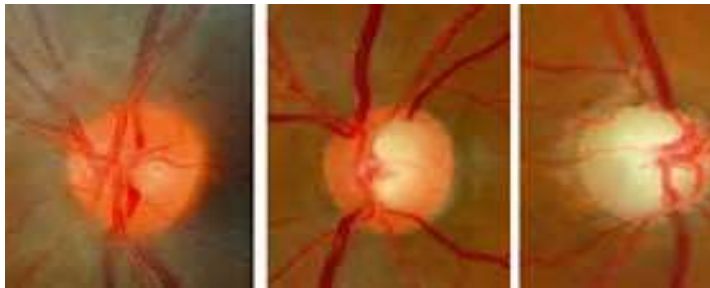

Acuut gesloten hoek glaucoom

Vs

Primair open hoek glaucoom

GLAUROOM

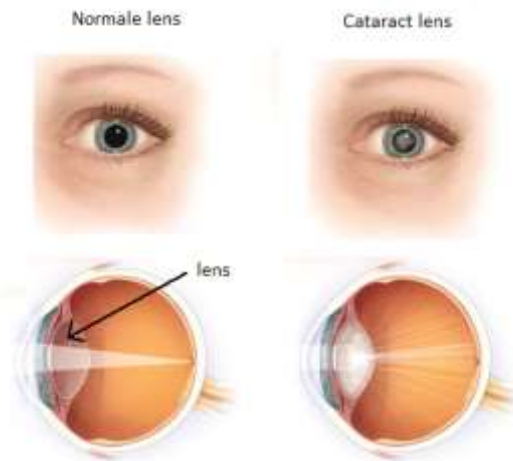


GLAUROOM


Screening vanaf 45jaar (familiaal belast: 40j)

Drukverlagende therapie
Glaucoommedicatie
Laseringrepen
Heelkundige ingrepen

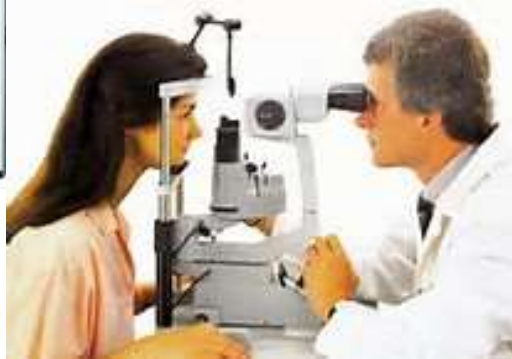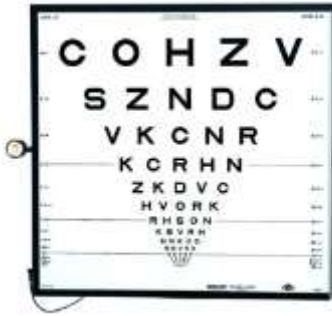
CATARACT



KLACHTEN bij CATARACT

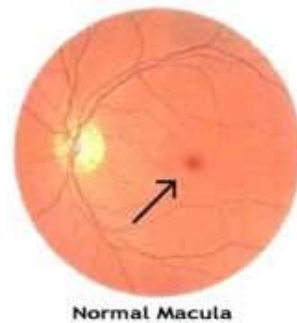
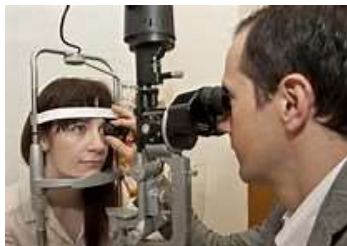

ONDERZOEKSMETHODES BIJ CATARACT

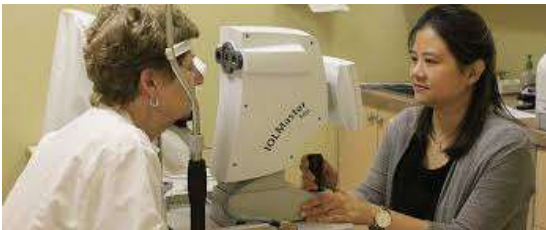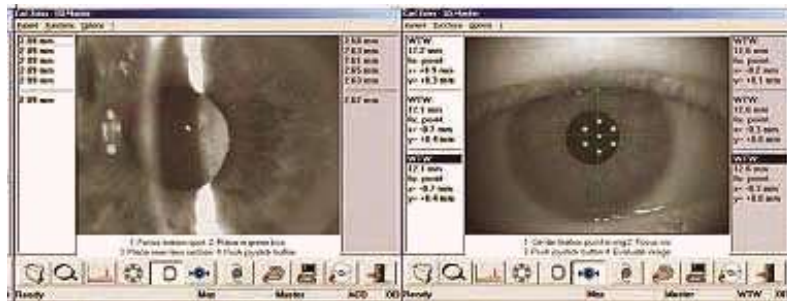


ONDERZOEKSMETHODES BIJ CATARACT

Cataractoperatie enkel
Als motor van het oog ook goed is nagezien!

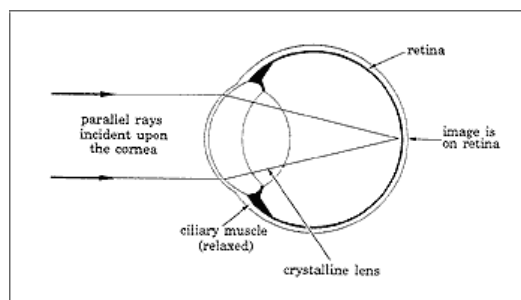


PREOPERATIEVE LENSBEREKENING

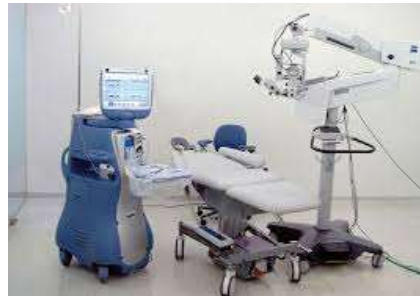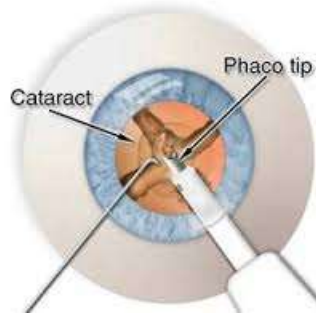


"BRILSTERKTE= A+B+C"

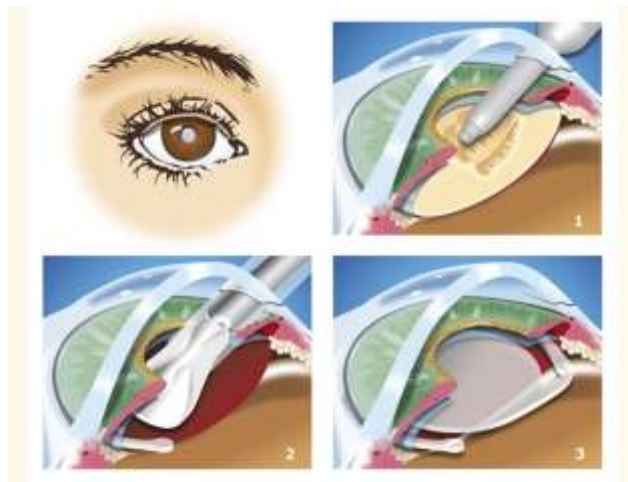
- A. Breking van cornea (~40D)
- B. Breking van de lens (~20D)
- C. Lengte van het oog (~23mm)



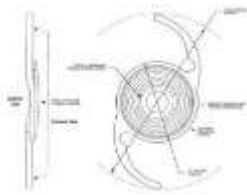

PHACO-EMULSIFICATIE



PHACO-EMULSIFICATIE en IMPLANTLENS



IMPLANTLENS

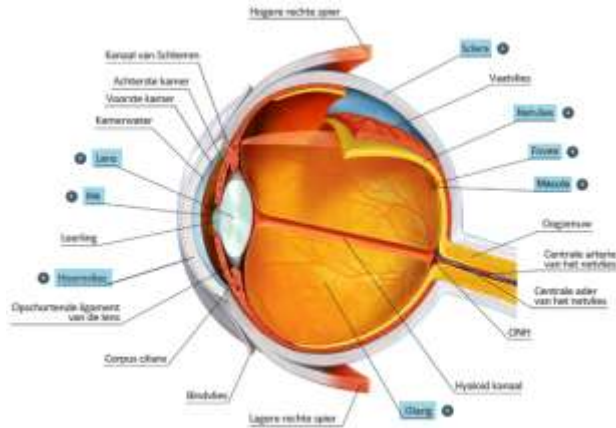


CATARACTINGREEP

<https://www.youtube.com/watch?v=NplAmgttT9A>

A promotional graphic for a cartoon about cataract surgery. The background is a bright yellow gradient with a sunburst pattern. In the center, there are large red quotation marks. Below them, the text "Cartoon Cataract Surgery" is written in bold black font. At the bottom right, the name "Timothy Root, M.D." is written in a smaller black font. In the bottom left corner, there is a small inset photograph of a man in a blue shirt speaking into a red microphone. At the very bottom left, the text "OphthoBook.com" is written in a bold, white font with a black outline.


ANATOMIE




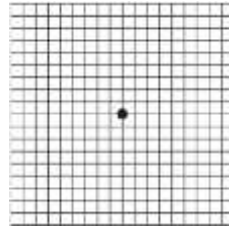
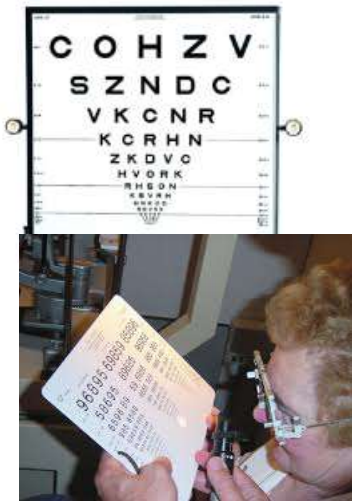
KLACHTEN bij LMD

Dit is een tekst die is afgedrukt op een stuk papier dat is gebogen. De tekst is onleesbaar vanwege de kromming en de kwaliteit van de afbeelding.

- Uni – bilateraal
- Subacuut
- Vooral leesproblemen
- Metamorfopsie; scotomen

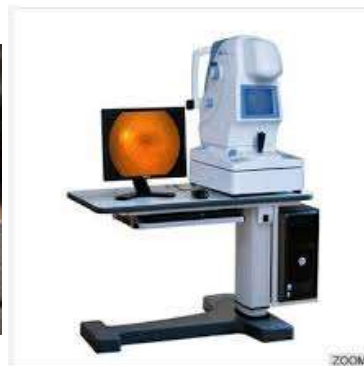
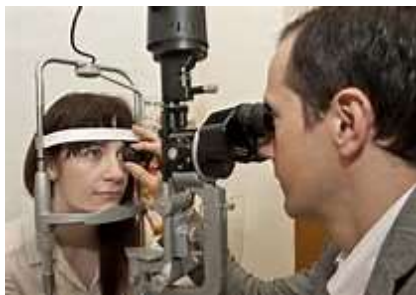
ONDERZOEKSMETHODES

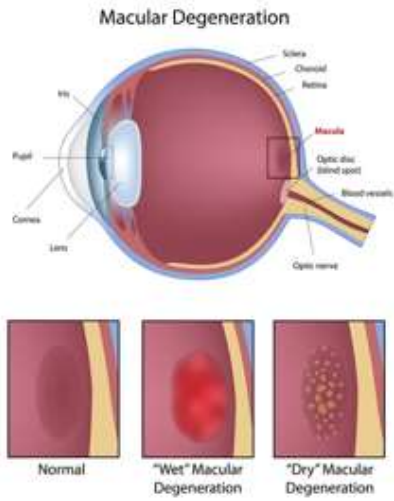


ONDERZOEKSMETHODES

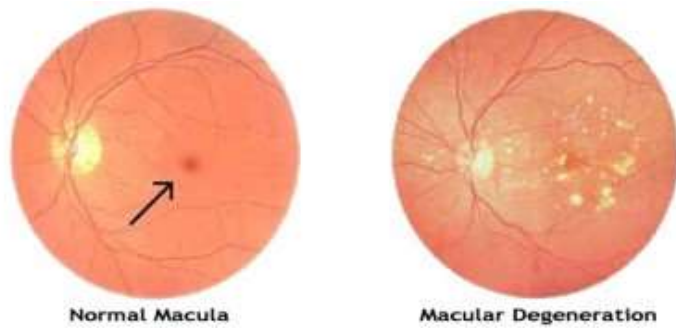
FUNDUSCOPIE/ FOTO'S



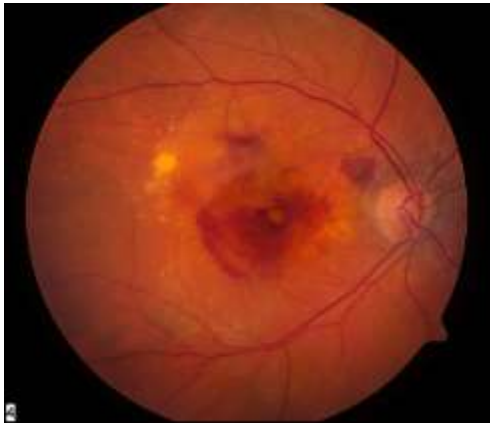soorten LMD



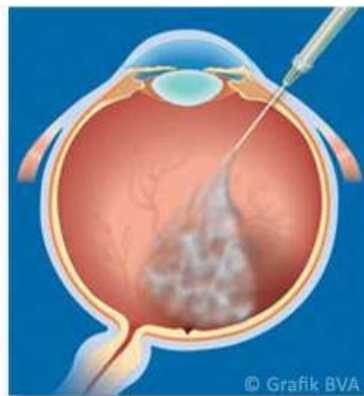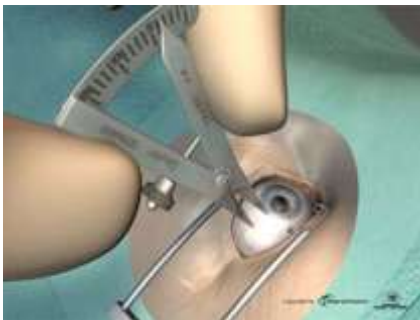
droge LMD



natte LMD



INTRAVITREALE INJECTIES

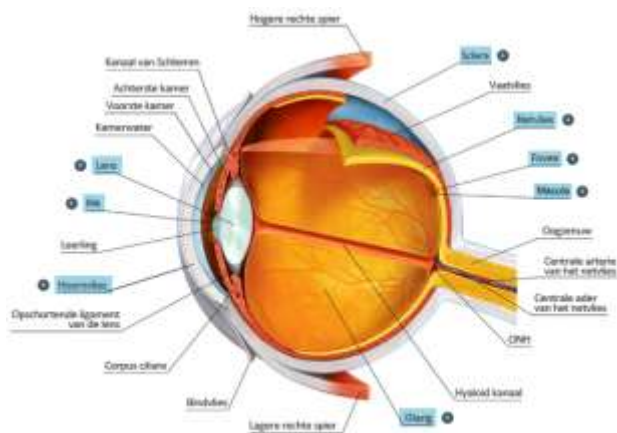


"FUNCTIONEEL BLIND"

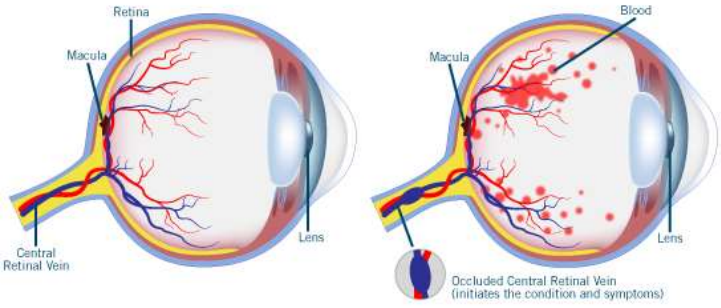


Retina (nog)
niet vervangbaar

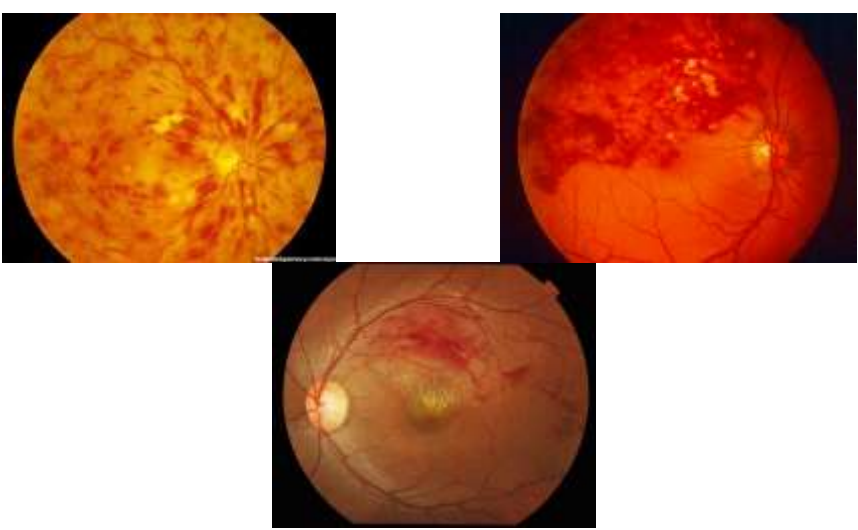
ANATOMIE



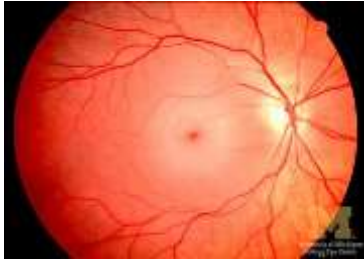VENEUSE OCCLUSIE



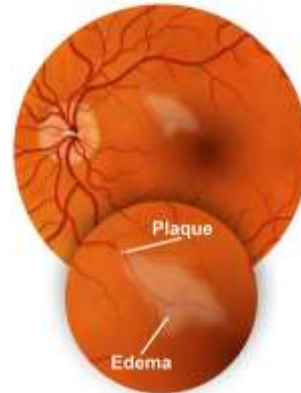
VENEUSE OCCLUSIE



ARTERIËLE OCCLUSIE




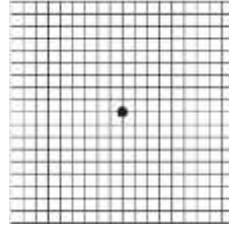
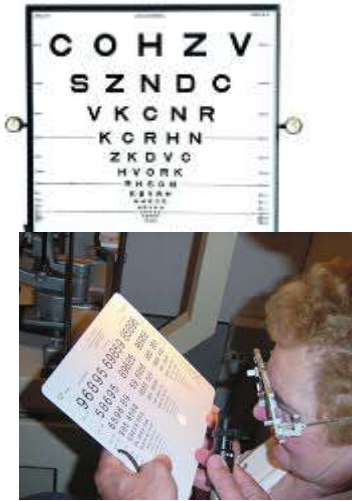
Branch Retinal Artery Occlusion



KLACHTEN BIJ TROMBOSE

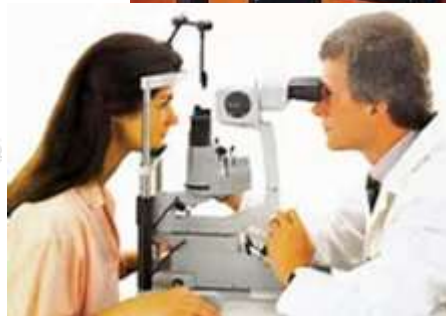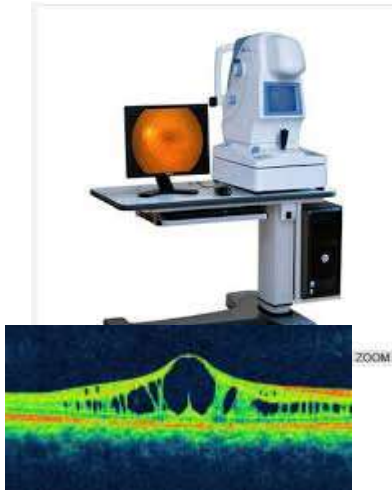
PLOTS
unilateraal
vertevisus én leesvisus gedaald
Metamorfopsie, scotomen

ONDERZOEKSMETHODES

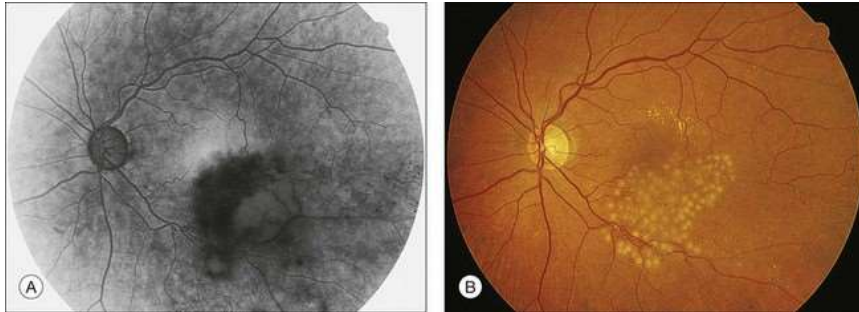


ONDERZOEKSMETHODES

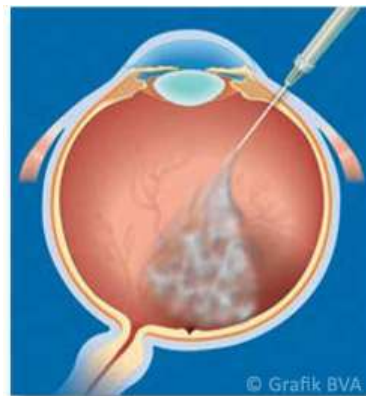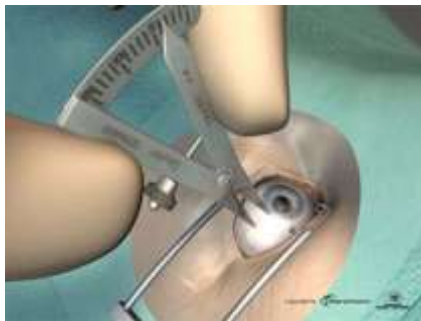
FUNDUS FOTO'S, OCT, FLUO-ANGIO



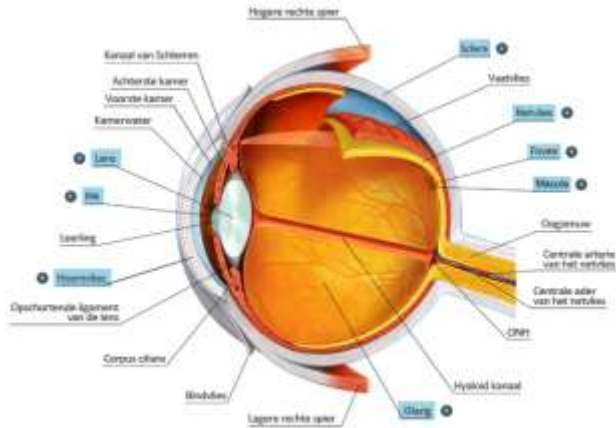
LASERTHERAPIE bij VENEUSE OCCLUSIE



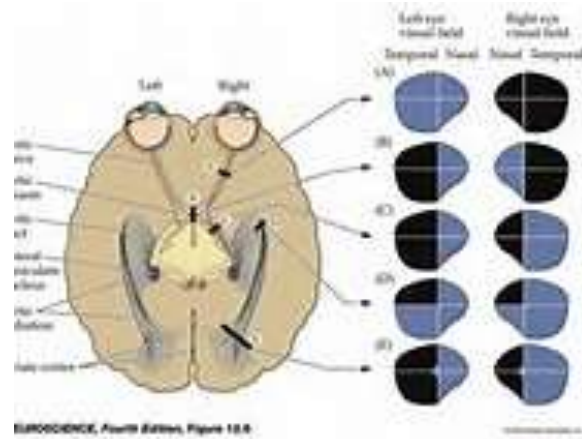
INTRAVITREALE INJECTIES



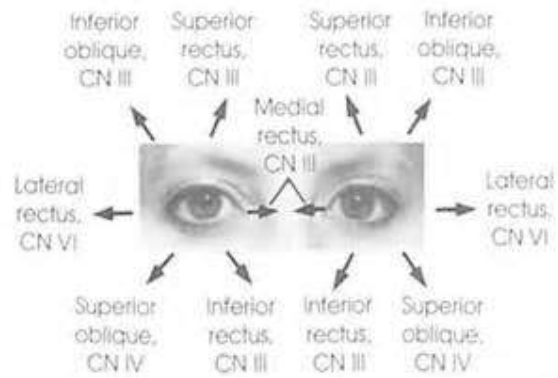
ANATOMIE



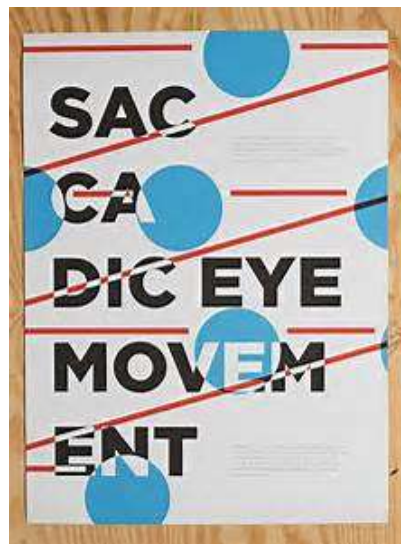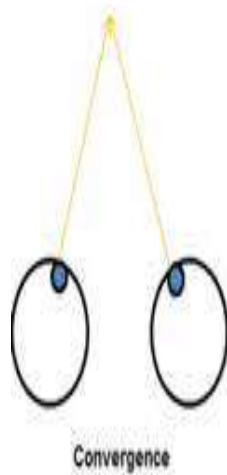
NEUROLOGISCH



NEUROLOGISCH



NEUROLOGISCH



OOGPROBLEMEN BINNEN DE GERIATRIE

Normale evolutie

- ° Presbyopie
- ° Drogere ogen

Pathologische evoluties

- ° glaucoom
- ° mediatroebelingen: cataract
- ° netvliesproblemen
 - ° leeftijdsgebonden maculopathie (LMD)
 - ° trombose (veneus, arterieel)
- ° neurologische problemen

Dank voor jullie aandacht!

